

ViewPoint 6

GE Healthcare



Helen M. OB Report
87688 Riverside Str
Chicago IL 21556

Date: 11/4/2010

Second Trimester Ultrasound

Indication Fetal anatomy survey.
History Blood type: O Rh positive. Smoking: yes.
Method Transabdominal ultrasound examination. Good view.
Pregnancy Singleton pregnancy. Number of fetuses: 1

	Date	Details	Gest. Age	EDC
LMP	6/17/2010	regular cycle	20 w + 0 d	3/24/2011
Agreed dating	Performed on 11/4/2010, based on ultrasound (AC, Femur)		22 w + 6 d	3/4/2011

General Evaluation Cardiac activity: present. Fetal movements: visualized.
Presentation: cephalic.
Placenta: anterior.
Umbilical cord: 3 vessel cord. Cord insertion: fetal insertion site normal.
Amniotic fluid: normal amount.

Fetal Biometry				
BPD	55.0 mm	22w 5d	42 %	Hadlock
OFD	68.0 mm	22w 5d	46 %	Jeanty
HC	209.0 mm	22w 6d	41 %	Hadlock
AC	180.9 mm	22w 6d	44 %	Hadlock
Femur	39.9 mm	22w 6d	39 %	Hadlock
EFW - Hadlock (BPD-HC-AC-FL)	600 g		60 %	Salomon

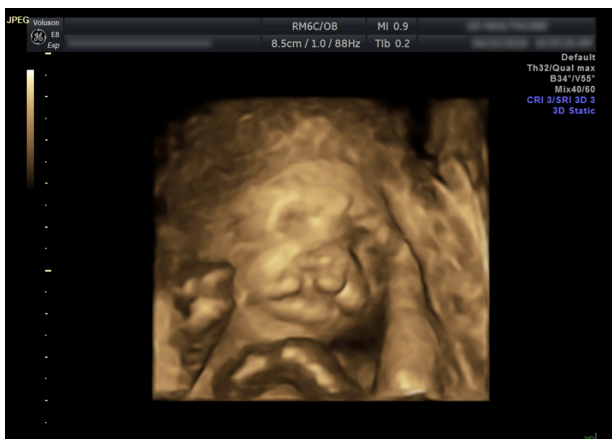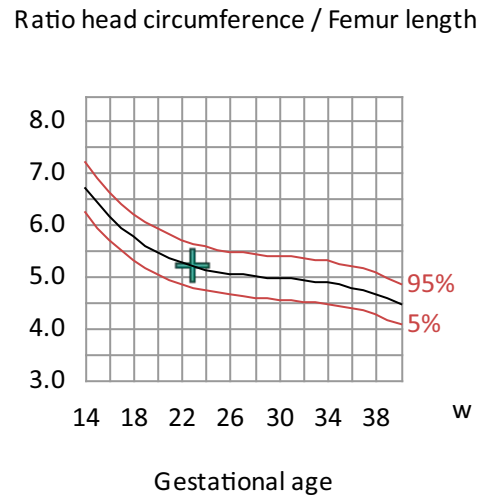
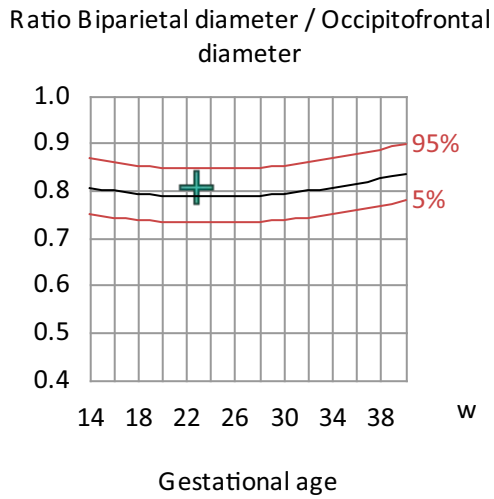
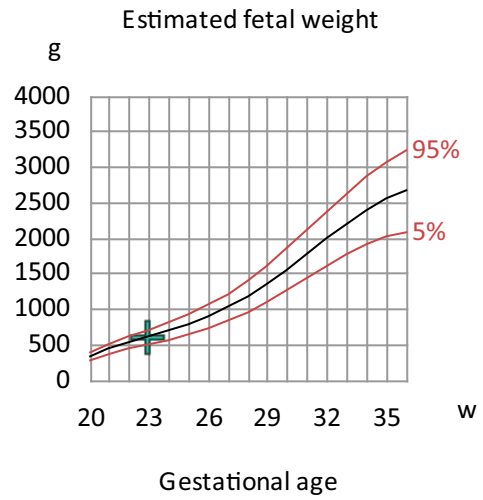
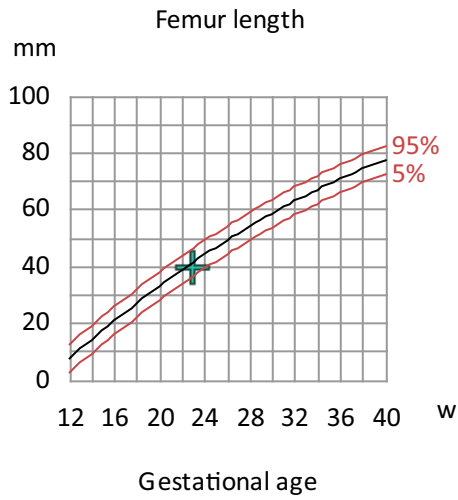
Fetal Anatomy The following structures could be visualized with normal appearance:
Head. Brain. Face. Neck. Spine. Thorax. Four chamber view. Cardiac position. Cardiac size. Great vessels. Abdominal wall. Gastrointestinal tract. Stomach. Kidneys. Bladder. Upper extremities. Lower extremities. Skeleton.

Abnormal structures:
Lips: Cleft maxilla: right unilateral, Cleft upper lip: right unilateral.

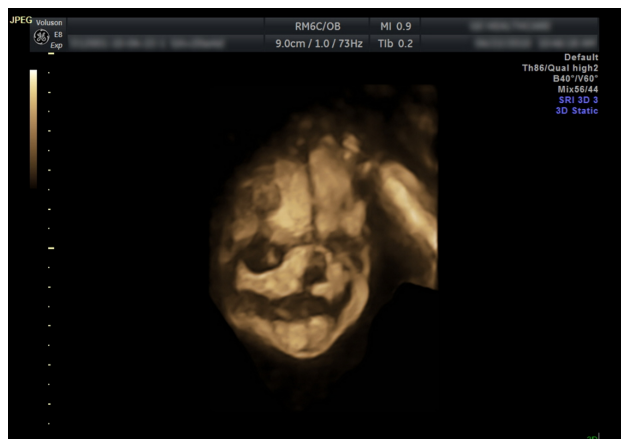
Maternal Structures Uterus and adnexa appear within normal limits,
No fibroids noted.

Impression Cleft maxilla: right unilateral, Cleft upper lip: right unilateral,
growth and anatomy survey otherwise appears normal.

Follow-up Repeat evaluation for fetal growth assessment and fetal monitoring is recommended.



B. Miller
Sonographer



Dr. W. Smith
Performing physician